

# Transplant Outcomes in Leukodystrophies

Paul J. Orchard and Jakub Tolar

Hematopoietic stem cell transplantation (HSCT) has been used for three decades as therapy for lysosomal storage diseases. Stable engraftment following transplantation has the potential to provide a source of an enzyme for the life of a patient. Recombinant enzyme is available for disorders that do not have a primary neurologic component. However, for diseases affecting the central nervous system (CNS), intravenous enzyme is ineffective due to its inability to cross the blood-brain barrier. For selected lysosomal disorders, including metachromatic leukodystrophy and globoid cell leukodystrophy, disease phenotype and the extent of disease at the time of transplantation are of fundamental importance in determining outcomes. Adrenoleukodystrophy is an X-linked, peroxisomal disorder, and in approximately 40% of cases a progressive, inflammatory condition develops in the CNS. Early in the course of the disease, allogeneic transplantation can arrest the disease process in cerebral adrenoleukodystrophy, while more advanced patients do poorly. In many of these cases, the utilization of cord blood grafts allows expedient transplantation, which can be critical in achieving optimal outcomes.

Semin Hematol 47:70-78. © 2010 Published by Elsevier Inc.

**L**eukodystrophies have been defined as inherited, metabolic disorders of myelin resulting in the progressive destruction of, or the failure to develop, normal white matter.<sup>1</sup> Oligodendrocytes are responsible for the production of myelin in the central nervous system (CNS), and oligodendrocyte dysfunction or loss is at the heart of the leukodystrophies.<sup>2</sup> However, in many of the leukodystrophies, abnormalities are also observed in the peripheral nervous system (PNS), contributing to the morbidity of these disorders.<sup>3</sup> The majority of these genetic diseases are associated with specific enzyme defects, with each enzyme responsible for the degradation of particular substrates. These enzymatic deficiencies lead to the accumulation of substrate, which directly or indirectly contributes to toxicity. Disorders such as metachromatic leukodystrophy and globoid cell leukodystrophy are caused by lysosomal enzyme deficiencies (Figure 1), and are inherited in an autosomal recessive fashion. In contrast, adrenoleukodystrophy is a peroxisomal disorder and is X-linked in inheritance. These three conditions are the primary disorders currently treated with allogeneic hematopoietic stem cell transplantation (HSCT), although

transplantation has been explored for a number of others as well.

In 1971 Porter et al demonstrated that the accumulation of sulfatide in cells derived from a patient with metachromatic leukodystrophy was corrected when arylsulfatase A (ARSA) was provided in the culture medium.<sup>4</sup> These experiments were similar to those performed by Neufeld's group several years earlier using Hurler and Hunter fibroblasts,<sup>5</sup> which were fundamentally important in demonstrating that lysosomal enzymes provided within the environment can be used by the cells from affected individuals, allowing the degradation of accumulated substrate. These studies provided the basis for the clinical use of transplantation for lysosomal diseases. In addition, Scaravilli and Jacobs documented that the abnormal myelination of the peripheral nerves of twitcher mice, a model of globoid cell leukodystrophy, can be improved following transplantation into trembler animals, another model of peripheral nerve disease.<sup>6</sup> Enzyme provided environmentally appeared to correct nerve tissue deficient in a lysosomal enzyme. Following the early success of allogeneic transplantation in Hurler syndrome,<sup>7</sup> transplant was explored as therapy for the leukodystrophies. The clinical and biologic characteristics of the various diseases will be discussed individually, including issues related to therapy using HSCT.

## METACHROMATIC LEUKODYSTROPHY

The term "metachromatic" refers to the staining pattern of sulfatides that accumulate in the cells of individu-

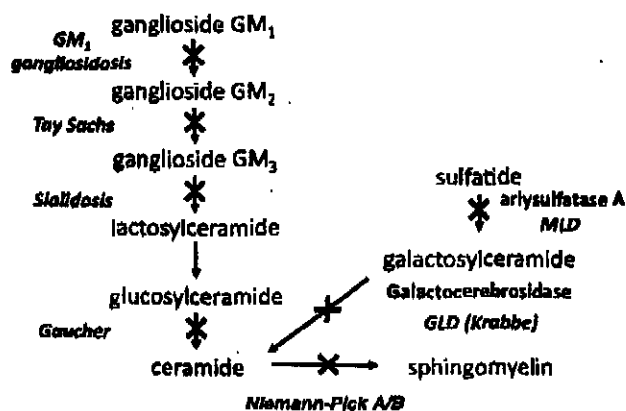
Department of Pediatrics, Division of Hematopoietic Stem Cell Transplantation, University of Minnesota, Minneapolis, MN.

Address correspondence to Paul J. Orchard, MD, Department of Pediatrics, Division of Hematopoietic Stem Cell Transplantation, University of Minnesota, 420 Delaware St SE, Mayo Mail Code 366, Minneapolis, MN 55455.

0037-1963/10/\$ - see front matter

© 2010 Published by Elsevier Inc.

doi:10.1053/j.seminhematol.2009.10.006



**Figure 1.** Lysosomal enzyme deficiencies associated with globoid cell leukodystrophy (GLD) and metachromatic leukodystrophy (MLD). Disorders resulting from various enzyme deficiencies are shown in italics.

als with metachromatic leukodystrophy.<sup>8</sup> Metachromatic leukodystrophy is an autosomal recessive lysosomal disorder caused by a defect in ARSA activity. Defects in the ARSA gene result in accumulation of the substrate cerebroside 3-sulfate, which is found primarily in myelin membranes.<sup>9</sup> The inability to degrade substrate leads to demyelination of the white matter of the CNS, as well as the peripheral nerves.<sup>10</sup> **ARSA deficiency leading to metachromatic leukodystrophy has an incidence of approximately 1:40,000 births,** while a higher frequency may be observed in specific populations.<sup>10-12</sup> The gene has been mapped to chromosome 22q13.31, and a large number of mutations within the gene have been described.<sup>10,13</sup> The diagnosis of metachromatic leukodystrophy is complicated due to the relatively high frequency of pseudodeficiency, a condition in which measured ARSA levels appear low due to a structural alteration within the ARSA gene, which may occur in up to 15% of the population.<sup>14,15</sup> While these modifications lead to abnormal ARSA testing in vitro, enzyme activity in regards to naturally occurring substrates is preserved.<sup>16</sup> Pseudodeficiency can be distinguished from metachromatic leukodystrophy by measuring the excretion of sulfatides in urine, as an abnormal level of sulfatide is observed in metachromatic leukodystrophy and not in pseudodeficiency. Additionally, as saposin B is required to solubilize lipid to make it accessible to ARSA, a deficiency in saposin B can result in a phenotype similar to metachromatic leukodystrophy, while ARSA activity in leukocytes or fibroblasts is normal.<sup>17</sup>

The clinical manifestations of metachromatic leukodystrophy are varied, and they are categorized based on age of onset. The most common phenotype is the late-infantile form of the disease, which affects children in the first years of life.<sup>18</sup> Affected children develop increasing difficulty with walking, and as the disease progresses, with standing and sitting. Later, increasing

motor deficits are observed, including indistinct speech, swallowing difficulties, and an inability to handle secretions. Eventually, death occurs, usually in 2-4 years from onset, although with more aggressive treatment patients can live significantly longer. Symptoms are associated with both central and peripheral demyelination, and motor-related difficulties may become apparent earlier than loss of cognition and language skills. Peripheral nerve dysfunction can be demonstrated with nerve conduction studies. The juvenile form of the disease has an onset from 4 years of age through adolescence. The features of the disease are similar to the infantile form, although the rate of progression is slower. In some cases a distinction is made between the early and later forms of juvenile metachromatic leukodystrophy, depending on whether the onset of disease occurs before or after 6 years of age.<sup>18,19</sup> The adult form of metachromatic leukodystrophy represents approximately 20% of cases, and the clinical aspects of the disorder may become apparent as late as the seventh decade.<sup>15</sup> However, rather than presenting with motor-related difficulties, affected patients may have emotional lability, progressive dementia, psychosis, and difficulties with substance abuse. There is a phenotype-genotype correlation in metachromatic leukodystrophy, with more severe mutations resulting in more rapid accumulation of sulfatides and disease progression; in contrast, if one of the alleles allows limited amounts of enzyme to be produced, later-onset phenotypes can be observed.<sup>13</sup>

The results of the first transplant for metachromatic leukodystrophy was reported by Krivit et al.<sup>20</sup> Many of the subsequent publications regarding transplantation for metachromatic leukodystrophy provide information for only a limited number of patients, and these may vary in phenotype (late-infantile, juvenile, or adult form), as well as the state of the disease at the time of transplantation.<sup>19</sup> **In addition, there is no universal standard for assessing patients prior to transplantation, nor for following their neurologic status after stem cell replacement. Such data are necessary to define the benefits and limitations of this therapy. As one would expect, patients early in their disease course, including those that are asymptomatic at transplantation, are more likely to have better outcomes, and similarly those with less severe phenotypes may respond better to therapy. It seems clear that HSCT has the ability to alter the course of later-onset disease. However, the available data do not support transplantation for symptomatic late-infantile disease: it seems likely that insufficient enzyme is delivered quickly enough to alter the rapid progression of disease, as the extent of CNS disease is dependent on engraftment of cells such as the microglial population in the brain.**<sup>19,21,22</sup>

**While the use of cord blood grafts can decrease the time from diagnosis to transplant, it is not clear that donor cell delivery to the CNS or PNS is different, either in the proportion of cells delivered or the kinet-**

ics of engraftment than with the use of a bone marrow graft. In addition, while it is possible that cord blood-derived cells better differentiate within the CNS than marrow, this is currently speculative. Whether transplant provides a benefit in asymptomatic patients predicted to have a late-infantile phenotype is unclear; available data suggest that these patients continue to have progressive motor disabilities, while cognitive parameters may be relatively spared.<sup>19,23,24</sup> Similarly, reports of the outcome of transplantation in patients with later-onset disease describe varied results. Older patients transplanted with symptomatic disease can achieve stabilization of the CNS,<sup>25,26</sup> although many continue to have peripheral nerve disease leading to progressive motor-related morbidity. Reports on the use of cord blood as a graft source have described disease stabilization, although outcomes may vary, even within a family.<sup>27</sup>

### GLOBOID CELL LEUKODYSTROPHY

The disorder known as globoid cell leukodystrophy was initially described in 1916 by Krabbe, and hence is also called Krabbe disease.<sup>28</sup> The term "globoid cell" refers to multinuclear macrophages present within the brain characteristically seen in this disorder. In 1970 the enzyme defect responsible for globoid cell leukodystrophy was identified as galactocerebroside  $\beta$ -galactosidase (GALC), a lysosomal enzyme;<sup>29</sup> this enzyme is also commonly referred to as galactocerebroxidase. The gene was localized to chromosome 14 in 1990,<sup>30</sup> and was cloned by Wenger's laboratory in 1993.<sup>31</sup> The primary substrate that accumulates in globoid cell leukodystrophy is galactocerebroside, which is degraded by GALC to ceramide and galactose.<sup>32</sup> Psychosine is another metabolite accumulating in globoid cell leukodystrophy that has been thought to be important in contributing to cytotoxicity of cells in the CNS, including oligodendrocytes.<sup>33-35</sup> Globoid cell leukodystrophy has a varied phenotype, and in this respect is similar to metachromatic leukodystrophy. The most common presentation is in early infancy, with an incidence of 1:70,000-100,000; patients characteristically become increasingly irritable, with developmental arrest and subsequent regression, and increased sensitivity to stimuli.<sup>36</sup> Protein determinations in the cerebral spinal fluid are high. Hypertonicity is apparent, with feeding difficulties and visual changes; increased deep tendon reflexes and seizures may be observed. Death generally results within a few years after the onset of symptoms. Other patients have less severe disease and have been divided into late-infantile (onset from 6 months-3 years) and juvenile forms (ages 3-8 years), while some patients are not diagnosed until their second or third decades, and occasionally later.<sup>36</sup> As might be expected, later-onset patients have a less rapidly progressive disease course.

Kravit reported the results of allogeneic transplantation for five patients with globoid cell leukodystrophy

in 1998.<sup>37</sup> Four of the patients had later-onset disease, while one had typical infantile globoid cell leukodystrophy. For the older patients, transplant appeared to stabilize, or even improve, their condition. The patient with infantile disease was transplanted at 2 months of age, and had a much different course than did a prior sibling who died of globoid cell leukodystrophy. There is now sufficient experience with transplantation of symptomatic patients with infantile disease to state that transplantation is not effective. In addressing this question, Escolar reported a means of clinically assessing patients with globoid cell leukodystrophy in the pre-transplant period, and correlated these assessments to outcomes.<sup>38</sup> There has recently been great interest in the outcomes of patients predicted to have infantile globoid cell leukodystrophy if transplantation is performed in the neonatal period. Very young, as yet asymptomatic, patients predicted to have a severe phenotype clearly have had a less severe clinical course than what would have been anticipated without transplantation.<sup>39</sup> Newborn screening has been proposed as a means of identifying patients prior to the onset of symptoms.<sup>40,41</sup> However, the long-term outcome of patients with severe genotypes who are transplanted in the first weeks remains uncertain.<sup>42</sup> Their significant motor limitations are likely at least in part to be due to peripheral nerve demyelination, as is observed in the twitcher mice, a model for globoid cell leukodystrophy.<sup>43-45</sup> There has not been universal agreement in favor of neonatal testing for globoid cell leukodystrophy, although screening is currently done in New York and is likely to be in place soon in several other states. Due to the severe time limitations in attempting to transplant asymptomatic neonates, a large proportion of these infants will require cord blood grafts.

The efficacy of transplantation in patients with later-onset globoid cell leukodystrophy remains less well delineated than would be expected. Patients with later-onset disease are likely to benefit from transplantation if undertaken early in the course of their disease.<sup>46</sup> However, data derived from a large series of patients that focused on function and neurocognitive outcomes are not available. It would be important to review the genotypic findings of an individual diagnosed by GALC activity to determine whether it is reasonable to pursue transplantation in an asymptomatic patient, as it is not necessarily clear what the anticipated course will be. However, if a patient with later-onset disease is in the early stages of the disease, transplantation seems a reasonable option. For a number of these diseases, multi-institutional trials with standard methods of analysis would prove very beneficial,<sup>47</sup> despite the difficulties inherent in developing and funding these large trials that could require decades to complete.

## ADRENOLEUKODYSTROPHY

### Clinical Manifestations of Adrenoleukodystrophy

Adrenoleukodystrophy was initially described in 1923 by Siemerling and Creutzfeld as a condition characterized by hyperpigmentation and central nervous system demyelination. In 1976 Igarashi and colleagues observed that saturated very-long-chain fatty acids, such as hexacosanoic acid (C:26:0), accumulate in the brain and adrenal tissue of patients with adrenoleukodystrophy.<sup>48</sup> Later, it was shown that excess very-long-chain fatty acids are also present in plasma,<sup>49</sup> especially C24 and C26 fatty acids.<sup>50</sup> The inability to degrade very-long-chain fatty acids in patients with adrenoleukodystrophy is due to mutations in a gene that encodes for a peroxisomal membrane protein, now designated *ABCD1* or adrenoleukodystrophy. The condition is X-linked in inheritance, and in males the finding of elevated very-long-chain fatty acids in the serum is sufficient to make the diagnosis. The disorder is seen in approximately 1 in 17,000 males, and seems to be similar in distribution across ethnic and racial groups.<sup>51,52</sup> Within a kindred, there is substantial clinical variability despite a single genotype. In the pediatric population (up to age 20), approximately 50% of boys develop adrenal insufficiency, while in 35% to 40% an acute, inflammatory, demyelinating condition develops, termed cerebral adrenoleukodystrophy.<sup>51</sup> In others, generally in the third or fourth decade of life, an axonal process develops in the spinal cord long tracts, termed adrenomyeloneuropathy.<sup>52</sup> This "adult form" of the disease is generally associated with a slow deterioration of motor function.

The reasons for phenotypic variability within a family are unclear. Accumulation of very-long-chain fatty acids seems to be followed by another insult of unknown etiology that initiates the inflammatory response characterized by increased synthesis of nitric oxide, cytokines, chemokines, and infiltration of inflammatory cells such as macrophages and T cells.<sup>53-56</sup> The "two-hit" hypothesis for cerebral adrenoleukodystrophy proposed by Eichler suggests that after the very-long-chain fatty acids accumulation has made the cell membrane vulnerable (first hit), additional injury occurs as a result of environmental changes (trauma, seizure, infection, etc) to stimulate the inflammatory changes. Alternatively, polymorphisms of immune response genes could underlie the varied spectrum of clinical presentation in hemizygotes with *ABCD1* mutations: from asymptomatic to the severe childhood cerebral form of adrenoleukodystrophy.

### Rationale for Allogeneic Stem Cell Transplantation for Cerebral Adrenoleukodystrophy

The median age of development of the cerebral form of adrenoleukodystrophy is 7 years old. No factors have

yet been identified that influence its emergence in a particular individual. The use of glyceryl trioleate-trierycinate oil (Lorenzo's oil) is being studied as a means of decreasing the levels of very-long-chain fatty acids, potentially reducing the proportion of patients developing the cerebral form of the disease. However, it is clear that when cerebral adrenoleukodystrophy develops, Lorenzo's oil is not of benefit in modifying the course of the disease.<sup>57</sup> A characteristic finding associated with cerebral adrenoleukodystrophy is inflammation of the white matter of the brain, with changes suggestive of active oxidative damage thought to be related to the inflammation.<sup>58</sup> In the vast majority of cases, cerebral disease is progressive once it has begun, leading to a vegetative state or death within several years of its onset. The only available therapy for cerebral adrenoleukodystrophy is allogeneic HSCT. Aubourg et al first reported the beneficial effect of HSCT in a boy with early-stage cerebral adrenoleukodystrophy in 1990,<sup>59</sup> following the earlier report of a patient with advanced disease who was transplanted and had a poor outcome.<sup>60</sup> The mechanism by which transplantation arrests the disease process is unknown. Transplantation may eliminate the inflammatory response, and this is responsible at least in part for the alteration in the course of the disease; after successful transplantation, progression of the disease can be arrested. Shapiro et al noted that disease stabilization persists for at least 5 to 10 years after transplantation.<sup>61</sup> At present, transplantation is the standard of care for boys with early-stage cerebral adrenoleukodystrophy. However, it is not clear that transplantation of an asymptomatic individual eliminates the possibility of the development of cerebral adrenoleukodystrophy, nor has it been demonstrated that HSCT prevents adrenomyeloneuropathy, as there are not sufficient numbers of patients in their second or third decade to address this issue. Based on this information, there is currently no rationale to transplant patients who do not have active cerebral adrenoleukodystrophy, as defined by white matter changes characteristic of cerebral adrenoleukodystrophy, with demonstrated gadolinium enhancement, which is thought to provide evidence of active inflammation.

### Physiologic Considerations of Transplantation for Cerebral Adrenoleukodystrophy

While the accumulation of very-long-chain fatty acids remains the biochemical hallmark of adrenoleukodystrophy and a useful diagnostic tool, it is not clear how very-long-chain fatty acid accumulation leads to the demyelination and inflammation of the CNS of boys with adrenoleukodystrophy. Accumulation of very-long-chain fatty acids leads to their incorporation into the phospholipid bilayer of the cellular membrane, which in some cases triggers an immune response

leading to the classic destructive lesions observed in adrenoleukodystrophy patients. While transplantation of metabolic lysosomal diseases such as metachromatic leukodystrophy and globoid cell leukodystrophy results in enzymatic delivery to deficient cells, the dysfunctional protein in adrenoleukodystrophy is not an enzyme; rather the product of the *ABCD1* gene is a structural protein—a peroxisomal transporter. As the *ABCD1* gene product is not expected to be freely secreted by cells, it is unlikely that there would be cross correction with adrenoleukodystrophy as occurs in the lysosomal disorders such as metachromatic leukodystrophy or globoid cell leukodystrophy. Animal models of adrenoleukodystrophy exist but do not develop cerebral pathology similar to human disease.<sup>62,63</sup> Thus, while one of the mechanisms by which transplantation arrests progression of adrenoleukodystrophy is assumed to be the elimination of cellular infiltration and inflammation,<sup>64</sup> the role of allogeneic, hematopoietic cells in controlling disease progression is not well understood. There may be cellular-based correction.<sup>65</sup> Microglial cell apoptosis also may be of importance in cerebral adrenoleukodystrophy,<sup>66</sup> and HSCT donor-derived microglial cells might provide a protective effect to the oligodendrocyte or other cell types. However, a better understanding of the etiology of the disease and the mechanisms by which therapy proves beneficial are clearly needed to design more effective strategies for improved outcomes in patients with adrenoleukodystrophy.

Of interest, Aubourg's group in Paris has had an open gene therapy protocol to treat boys with early cerebral disease using autologous bone marrow-derived CD34<sup>+</sup> cells that have been transduced with wild-type *ABCD1* gene in a lentiviral backbone. This is based on prior studies suggesting viral-mediated gene transfer can result in a decrease in very-long-chain fatty acids in adrenoleukodystrophy fibroblasts.<sup>67</sup> In the clinical studies, according to data presented at national meetings, approximately 20% of cells expressed the transgene in a stable fashion and, after early progression, disease stabilization was achieved (P. Aubourg, personal communication). Assuming that some of the progeny of these cells are microglia capable of homing to the brain, such stem cell gene therapy may provide a treatment option in future. In addition, these experiments provide data that complete correction of the hematopoietic cell population is not necessary.

### Outcomes of Transplantation for Cerebral Adrenoleukodystrophy

It has been well established that the outcomes of HSCT have been dramatically different in patients with early disease compared to results in those with more advanced disease.<sup>23,50,52,61,68-70</sup> When evaluated by a neuroimaging severity method (Loes score),<sup>71</sup> patients

with a score <9 and a performance intelligence quotient >80 had a 5-year survival rate of 92%.<sup>68</sup> This sharply contrasted to the patients with higher Loes scores who had a 5-year survival rate of about 45%. Patients who were transplanted very late in the course of their disease, with Loes scores >13, have not survived with standard transplant techniques.<sup>70</sup> Our group has shown that peritransplant anti-oxidant therapy with N-acetyl-L-cysteine (NAC) has promise in the treatment of patients with advanced adrenoleukodystrophy.<sup>70</sup> This is in contrast to the overwhelming evidence from previous decades when HSCT alone led to no change in the rapidly deteriorating natural history of late cerebral adrenoleukodystrophy. More experience is clearly needed to improve outcomes of patients with more advanced disease. Whether cord blood graft sources will prove advantageous in comparison to marrow grafts is as yet unclear. There has been speculation, yet unproven, that cord blood cells may have a greater ability to provide an undifferentiated cell population. There are no clinical data that outcomes are better with cord blood grafts than other sources. However, for patients with rapidly progressive disease, there are advantages in expedient access to cord blood grafts, which could influence outcomes.

### CURRENT CONTROVERSIES IN HEMATOPOIETIC CELL THERAPY OF LEUKODYSTROPHIES

Despite the experience of several decades in the use of transplantation for inherited metabolic disorders affecting the CNS, there is much that remains unclear, including the following:

1. The majority of physicians transplanting these patients would agree that, with current techniques, outcomes are poor for transplantation for symptomatic infantile globoid cell leukodystrophy and metachromatic leukodystrophy. However, whether patients transplanted very early in life (several weeks of age) will have acceptable outcomes is not yet clear. Resolving this has important implications, as there has been a movement towards newborn screening for these disorders,<sup>40-42</sup> and the use of screening generally assumes an adequate therapy is available. For newborn screening for adrenoleukodystrophy, in contrast, it has been demonstrated that patients with early cerebral adrenoleukodystrophy have very good outcomes with transplantation, but the current accepted practice is that only those with active cerebral disease should be transplanted.
2. The outcomes of transplanted patients with later onset globoid cell leukodystrophy and metachromatic leukodystrophy are much less clear than would be expected, in part due to the rare nature

of these diseases. This is due to the variability of disease status at transplant, the rate of progression, and difficulty in defining the neurologic endpoints. Establishing collaborative studies that have well defined outcomes will be a key factor in better determining the role of transplantation, and in order to counsel families making treatment decisions.

3. There is no consensus as to how grafts should be chosen for transplants. Clearly, for rapidly progressive disease, cord blood transplantation provides great advantages in contrast to unrelated donor grafts. However, if timing is less important, there is no compelling information to assist in choosing between an unrelated graft and a cord blood unit. While, with an unrelated donor, there is generally a reassuring clinical history, it is possible, although highly unlikely, that a cord could be chosen that is also deficient in the therapeutic gene of interest. We have adopted the strategy of testing a cord blood unit under consideration for transplantation for activity of the enzyme in question. However, we have not chosen cords based on enzyme levels, as these tests are very difficult to interpret given the variability in quality of the samples available for analysis. With these testing limitations, choosing a cord unit based on enzyme expression could lead to the use of a graft that is less well matched, or contains a lower cell dose, which could be counterproductive in relation to engraftment, graft-versus-host disease, and other factors. Another important issue related to the choice of graft source concerns sibling donors that are carriers. Would using a heterozygous donor, with a probable lower enzyme level, result in a worse outcome? While this may be presumed, data to support this assumption are lacking.
4. Will there be advantages in using reduced intensity regimens? For patients with ongoing neurologic injury, a preparative regimen that contributes to CNS toxicity is counterproductive. However, achieving rapid engraftment of microglia in the CNS may be critical in achieving disease stabilization, as it is thought that this population plays a therapeutic role in transplantation for these disorders.<sup>72,73</sup> The use of various techniques may assist in achieving microglial engraftment,<sup>74,75</sup> although there is little information to allow us to design preparative regimens that are non-toxic but effective in achieving expedient, full replacement of microglia with donor-derived cells.
5. Is there a role for transplantation as therapy for other metabolic diseases affecting the CNS? These disorders include Tay-Sachs and the related Sandhoff disease, which generally are rapidly progressive disorders, and symptomatic patients have done poorly with transplant. Niemann-Pick A, GM<sub>1</sub> gangliosidosis, and neuropathogenic Hunter and Gau-

cher syndromes could also be considered in this category. Again, whether transplantation very early in life can lead to acceptable outcomes is unclear. In addition, as novel therapies become available, such as enzyme replacement, substrate inhibition, anti-inflammatory agents, chaperone therapy, and others, improved results may be obtained in comparison to any single modality of therapy, including transplantation.

In summary, a large amount of data confirm that allogeneic transplantation can alter neurologic progression of inherited leukodystrophies, including metachromatic leukodystrophy, globoid cell leukodystrophy, and adrenoleukodystrophy. For example, allogeneic transplantation is considered the standard of care for boys with early cerebral adrenoleukodystrophy. However, while there is agreement that symptomatic infants with metachromatic leukodystrophy and globoid cell leukodystrophy do poorly, specific recommendations for the use of transplantation for metachromatic leukodystrophy and globoid cell leukodystrophy are more difficult. Additional information regarding outcomes in patients with later-onset metachromatic leukodystrophy/globoid cell leukodystrophy undergoing HSCT is lacking. The field would greatly benefit from multi-institutional studies or registry data, assuming there is a relatively uniform means of assessing the neurologic status of these patients. Much remains to be understood in regards to factors affecting disease progression, including CNS versus PNS disease, the utility of combination therapy, and protective agents such as NAC. Providing answers through basic and clinical research will prove important for the treatment of these rare but devastating disorders.

## REFERENCES

1. Berger J, Moser HW, Forss-Petter S. Leukodystrophies: recent developments in genetics, molecular biology, pathogenesis and treatment. *Curr Opin Neurol.* 2001;14:305-12.
2. Goldman SA, Schanz S, Windrem MS. Stem cell-based strategies for treating pediatric disorders of myelin. *Hum Mol Genet.* 2008;17:R76-83.
3. Aicardi J. The inherited leukodystrophies: a clinical overview. *J Inher Metab Dis.* 1993;16:733-43.
4. Porter MT, Fluharty AL, Kihara H. Correction of abnormal cerebroside sulfate metabolism in cultured metachromatic leukodystrophy fibroblasts. *Science.* 1971;172:1263-5.
5. Fratantoni JC, Hall CW, Neufeld EF. Hurler and Hunter syndromes: mutual correction of the defect in cultured fibroblasts. *Science.* 1968;162:570-2.
6. Scaravilli F, Jacobs JM. Improved myelination in nerve grafts from the leukodystrophic twitcher into trembler mice: evidence for enzyme replacement. *Brain Res.* 1982;237:163-72.
7. Hobbs JR. Bone marrow transplantation for inborn errors. *Lancet.* 1981;2:735-9.

8. Suzuki K, Chen G. Metachromatic leucodystrophy: isolation and chemical analysis of metachromatic granules. *Science*. 1966;151:1231-3.
9. Gieselmann V, Polten A, Krcysing J, von Figura K. Molecular genetics of metachromatic leukodystrophy. *J Inher Metab Dis*. 1994;17:500-9.
10. Eng B, Nakamura LN, O'Reilly N, Schokman N, Nowaczyk MM, Krivit W, et al. Identification of nine novel arylsulfatase A (ARSA) gene mutations in patients with metachromatic leukodystrophy (metachromatic leukodystrophy). *Hum Mutat*. 2003;22:418-9.
11. Heinisch U, Zlotogora J, Kafert S, Gieselmann V. Multiple mutations are responsible for the high frequency of metachromatic leukodystrophy in a small geographic area. *Am J Hum Genet*. 1995;56:51-7.
12. Zlotogora J, Bach G, Bosenberg C, Barak Y, von Figura K, Gieselmann V. Molecular basis of late infantile metachromatic leukodystrophy in the Habbanite Jews. *Hum Mutat*. 1995;5:137-43.
13. Gieselmann V. Metachromatic leukodystrophy: genetics, pathogenesis and therapeutic options. *Acta Paediatr Suppl* 2008;97:15-21.
14. Fuharty AL, Meek WE, Kihara H. Pseudo arylsulfatase A deficiency: evidence for a structurally altered enzyme. *Biochem Biophys Res Commun*. 1983;112:191-7.
15. Sedel F, Tourbah A, Fontaine B, Lubetzi C, Baumann N, Saudubray JM, et al. Leukoencephalopathies associated with inborn errors of metabolism in adults. *J Inher Metab Dis*. 2008;31:295-307.
16. Herz B, Bach G. Arylsulfatase A in pseudodeficiency. *Hum Genet*. 1984;66:147-50.
17. Gieselmann V, Zlotogora J, Harris A, Wenger DA, Morris CP. Molecular genetics of metachromatic leukodystrophy. *Human Mutat*. 1994;4:233-42.
18. Scriver CR, Sly WS, Childs B, Beaudet AL, Valle D, Kinzler KW, et al. The metabolic and molecular bases of inherited disease. 8th ed. New York: McGraw-Hill Professional; 2001. p. 3695-724.
19. Biffi A, Lucchini G, Rovelli A, Sessa M. Metachromatic leukodystrophy: an overview of current and prospective treatments. *Bone Marrow Transplant*. 2008;42 Suppl 2: S2-6.
20. Krivit W, Shapiro E, Kennedy W, Lipton M, Lockman L, Smith S, et al. Treatment of late infantile metachromatic leukodystrophy by bone marrow transplantation. *N Engl J Med*. 1990;322:28-32.
21. Orchard PJ, Blazar BR, Wagner J, Charnas L, Krivit W, Tolar J. Hematopoietic cell therapy for metabolic disease. *J Pediatr*. 2007;151:340-6.
22. Peters C, Krivit W. Metabolic diseases. In: Ball E, editor. Hematopoietic stem cell therapy. Philadelphia: Churchill Livingstone; 2000. p. 169-83.
23. Peters C, Steward CG. Hematopoietic cell transplantation for inherited metabolic diseases: an overview of outcomes and practice guidelines. *Bone Marrow Transplant*. 2003;31:229-39.
24. Peters C. Hematopoietic stem cell transplantation for storage diseases. In: Appelbaum FR, Forman SJ, Negrin RS, editors. Thomas' hematopoietic cell transplantation: stem cell transplantation. 4th ed. Oxford, UK: Wiley; 2009. p. 1136-62.
25. Gorg M, Wilck W, Granitzny B, Suerken A, Lukacs Z, Ding X, et al. Stabilization of juvenile metachromatic leukodystrophy after bone marrow transplantation: a 13-year follow-up. *J Child Neurol*. 2007;22:1139-42.
26. Solders G, Celsing G, Hagenfeldt L, Ljungman P, Isberg B, Ringden O. Improved peripheral nerve conduction, EEG and verbal IQ after bone marrow transplantation for adult metachromatic leukodystrophy. *Bone Marrow Transplant*. 1998;22:1119-22.
27. Pierson TM, Bonnemann CG, Finkel RS, Bunin N, Tennekoon GI. Umbilical cord blood transplantation for juvenile metachromatic leukodystrophy. *Ann Neurol*. 2008;64:583-7.
28. Krabbe K. A new familial, infantile form of diffuse brain sclerosis. *Brain*. 1916;39:74-114.
29. Suzuki K, Suzuki Y. Globoid cell leukodystrophy (Krabbe's disease): deficiency of galactocerebroside beta-galactosidase. *Proc Natl Acad Sci U S A*. 1970;66:302-9.
30. Zlotogora J, Chakraborty S, Knowlton RG, Wenger DA. Krabbe disease locus mapped to chromosome 14 by genetic linkage. *Am J Hum Genet*. 1990;47:37-44.
31. Chen YQ, Rafi MA, de Gala G, Wenger DA. Cloning and expression of cDNA encoding human galactocerebroside, the enzyme deficient in globoid cell leukodystrophy. *Hum Mol Genet*. 1993;2:1841-5.
32. Tatsumi N, Inui K, Sakai N, Fukushima H, Nishimoto J, Yanagihara I, et al. Molecular defects in Krabbe disease. *Hum Mol Genet*. 1995;4:1865-8.
33. Igisu H, Suzuki K. Progressive accumulation of toxic metabolite in a genetic leukodystrophy. *Science*. 1984;224:753-5.
34. Suzuki K. Twenty five years of the "psychosine hypothesis": a personal perspective of its history and present status. *Neurochem Res*. 1998;23:251-9.
35. White AB, Givogri MI, Lopez-Rosas A, Cao H, van Breemen R, Thinakaran G, et al. Psychosine accumulates in membrane microdomains in the brain of krabbe patients, disrupting the raft architecture. *J Neurosci*. 2009;29:6068-77.
36. Scriver CR, Sly WS, Childs B, Beaudet AL, Valle D, Kinzler KW, et al. The metabolic and molecular bases of inherited disease. New York: McGraw-Hill Professional; 2001. p. 3669-94.
37. Krivit W, Shapiro EG, Peters C, Wagner JE, Cornu G, Kurtzberg J, et al. Hematopoietic stem-cell transplantation in globoid-cell leukodystrophy. *N Engl J Med*. 1998;338:1119-26.
38. Escolar ML, Poe MD, Martin HR, Kurtzberg J. A staging system for infantile Krabbe disease to predict outcome after unrelated umbilical cord blood transplantation. *Pediatrics*. 2006;118:e879-89.
39. Escolar ML, Poe MD, Provenzale JM, Richards KC, Allison J, Wood S, et al. Transplantation of umbilical-cord blood in babies with infantile Krabbe's disease. *N Engl J Med*. 2005;352:2069-81.
40. Duffner PK, Caggana M, Orsini JJ, Wenger DA, Patterson MC, Crosley CJ, et al. Newborn screening for Krabbe disease: the New York State model. *Pediatr Neurol*. 2009;40:245-52.
41. Meikle PJ, Grasby DJ, Dean CJ, Lang DL, Bockmann M, Whittle AM, et al. Newborn screening for lysosomal storage disorders. *Mol Genet Metab*. 2006;88:307-14.

42. Duffner PK, Caviness VS, Jr., Erbe RW, Patterson MC, Schultz KR, Wenger DA, et al. The long-term outcomes of presymptomatic infants transplanted for Krabbe disease: report of the workshop held on July 11 and 12, 2008, Holiday Valley, New York. *Genet Med*. 2009;11:450-4.
43. Kagitani-Shimono K, Mohri I, Yagi T, Taniike M, Suzuki K. Peripheral neuropathy in the twitcher mouse: accumulation of extracellular matrix in the endoneurium and aberrant expression of ion channels. *Acta Neuropathol*. 2008;115:577-87.
44. Kondo A, Hoogerbrugge PM, Suzuki K, Poorthuis BJ, Van Bekkum DW, Suzuki K. Pathology of the peripheral nerve in the twitcher mouse following bone marrow transplantation. *Brain Res*. 1988;460:178-83.
45. Luzi P, Rafi MA, Zaka M, Rao HZ, Curtis M, Vanier MT, et al. Biochemical and pathological evaluation of long-lived mice with globoid cell leukodystrophy after bone marrow transplantation. *Mol Genet Metab*. 2005;86:150-9.
46. Lim ZY, Ho AY, Abrahams S, Fensom A, Aldouri M, Pagliuca A, et al. Sustained neurological improvement following reduced-intensity conditioning allogeneic haematopoietic stem cell transplantation for late-onset Krabbe disease. *Bone Marrow Transplant*. 2008;41:831-2.
47. Cartier N, Aubourg P. Hematopoietic stem cell gene therapy in Hurler syndrome, globoid cell leukodystrophy, metachromatic leukodystrophy and X-adrenoleukodystrophy. *Curr Opin Mol Ther*. 2008;10:471-8.
48. Igarashi M, Schaumburg HH, Powers J, Kishimoto Y, Kolodny E, Suzuki K. Fatty acid abnormality in adrenoleukodystrophy. *J Neurochem*. 1976;26:851-60.
49. Moser AB, Kreiter N, Bezman L, Lu S, Raymond GV, Naidu S, et al. Plasma very long chain fatty acids in 3,000 peroxisome disease patients and 29,000 controls. *Ann Neurol*. 1999;45:100-10.
50. Moser HW. Clinical and therapeutic aspects of adrenoleukodystrophy and adrenomyeloneuropathy. *J Neuropathol Exp Neurol*. 1995;54:740-5.
51. Mahmood A, Dubey P, Moser HW, Moser A. X-linked adrenoleukodystrophy: Therapeutic approaches to distinct phenotypes. *Pediatr Transplant*. 2005;9 Suppl:55-62.
52. Moser HW, Raymond GV, Dubey P. Adrenoleukodystrophy: new approaches to a neurodegenerative disease. *JAMA*. 2005;294:3131-4.
53. Powers JM, Liu Y, Moser AB, Moser HW. The inflammatory myelinopathy of adreno-leukodystrophy: cells, effector molecules, and pathogenetic implications. *J Neuropathol Exp Neurol*. 1992;51:630-43.
54. McGuinness MC, Griffin DE, Raymond GV, Washington CA, Moser HW, Smith KD. Tumor necrosis factor-alpha and X-linked adrenoleukodystrophy. *J Neuroimmunol*. 1995;61:161-9.
55. McGuinness MC, Smith KD. Cerebral inflammation in X-linked adrenoleukodystrophy. *Arch Immunol Ther Exp*. 1999;47:281-7.
56. Paintlia AS, Gilg AG, Khan M, Singh AK, Barbosa E, Singh I. Correlation of very long chain fatty acid accumulation and inflammatory disease progression in childhood X-adrenoleukodystrophy: implications for potential therapies. *Neurobiol Dis*. 2003;14:425-39.
57. Moser HW, Powers JM, Smith KD. Adrenoleukodystrophy: molecular genetics, pathology, and Lorenzo's oil. *Brain Pathol*. 1995;5:259-66.
58. Powers JM, Pei Z, Heinzer AK, Deering R, Moser AB, Moser HW, et al. Adreno-leukodystrophy: oxidative stress of mice and men. *J Neuropathol Exp Neurol*. 2005;64:1067-79.
59. Aubourg P, Blanche S, Jambaque I, Rocchiccioli F, Kalifa G, Naud-Saudreau C, et al. Reversal of early neurologic and neuroradiologic manifestations of X-linked adrenoleukodystrophy by bone marrow transplantation. *N Engl J Med*. 1990;322:1860-6.
60. Moser HW, Tutschka PJ, Brown FR 3rd, Moser AE, Yeager AM, Singh I, et al. Bone marrow transplant in adrenoleukodystrophy. *Neurology*. 1984;34:1410-7.
61. Shapiro E, Krivit W, Lockman L, Jambaque I, Peters C, Cowan M, et al. Long-term effect of bone-marrow transplantation for childhood-onset cerebral X-linked adrenoleukodystrophy. *Lancet*. 2000;356:713-8.
62. Lu JF, Lawler AM, Watkins PA, Powers JM, Moser AB, Moser HW, et al. A mouse model for X-linked adrenoleukodystrophy. *Proc Natl Acad Sci U S A*. 1997;94:9366-71.
63. Yamada T, Shinnoh N, Kondo A, Uchiyama A, Shimozawa N, Kira J, et al. Very-long-chain fatty acid metabolism in adrenoleukodystrophy protein-deficient mice. *Cell Biochem Biophys*. 2000;32:239-46.
64. Eichler F, Van Haren K. Immune response in leukodystrophies. *Pediatric Neurology*. 2007;37:235-44.
65. Yamada T, Ohyagi Y, Shinnoh N, Kikuchi H, Osogawa M, Ochi H, et al. Therapeutic effects of normal cells on ABCD1 deficient cells in vitro and hematopoietic cell transplantation in the X-adrenoleukodystrophy mouse model. *J Neurol Sci*. 2004;218:91-7.
66. Eichler FS, Ren JQ, Cossoy M, Rietsch AM, Nagpal S, Moser AB, et al. Is microglial apoptosis an early pathogenic change in cerebral X-linked adrenoleukodystrophy? *Ann Neurol*. 2008;63:729-42.
67. Flavigny E, Sanhaj A, Aubourg P, Cartier N. Retroviral-mediated adrenoleukodystrophy-related gene transfer corrects very long chain fatty acid metabolism in adrenoleukodystrophy fibroblasts: implications for therapy. *FEBS Lett*. 1999;448:261-4.
68. Peters C, Charnas LR, Tan Y, Ziegler RS, Shapiro EG, DeFor T, et al. Cerebral X-linked adrenoleukodystrophy: the international hematopoietic cell transplantation experience from 1982 to 1999. *Blood*. 2004;104:881-8.
69. Boelens JJ. Trends in haematopoietic cell transplantation for inborn errors of metabolism. *J Inher Metab Dis*. 2006;29:413-20.
70. Tolar J, Orchard PJ, Bjoraker KJ, Ziegler RS, Shapiro EG, Charnas L. N-acetyl-L-cysteine improves outcome of advanced cerebral adrenoleukodystrophy. *Bone Marrow Transplant*. 2007;39:211-5.
71. Loes DJ, Stillman AE, Hite S, Shapiro E, Lockman L, Latchaw RE, et al. Childhood cerebral form of adrenoleukodystrophy: short-term effect of bone marrow transplantation on brain MR observations. *AJNR Am J Neuroradiol*. 1994;15:1767-71.
72. Krivit W, Sung JH, Shapiro EG, Lockman LA. Microglia: the effector cell for reconstitution of the central nervous system following bone marrow transplantation for lyso-



- somal and peroxisomal storage diseases. *Cell Transplant.* 1995;4:385-92.
73. Kennedy DW, Abkowitz JL. Kinetics of central nervous system microglial and macrophage engraftment: analysis using a transgenic bone marrow transplantation model. *Blood.* 1997;90:986-93.
74. Priller J, Flugel A, Wehner T, Boentert M, Haas CA, Prinz M, et al. Targeting gene-modified hematopoietic cells to the central nervous system: use of green fluorescent protein uncovers microglial engraftment. *Nat Med.* 2001;7:1356-61.
75. Tanaka R, Komine-Kobayashi M, Mochizuki H, Yamada M, Furuya T, Migita M, et al. Migration of enhanced green fluorescent protein expressing bone marrow-derived microglia/macrophage into the mouse brain following permanent focal ischemia. *Neuroscience.* 2003;117:531-9.